

PERMANENT PACEMAKER IMPLANTATION IN A 1200G-PRETERM SUFFERING FROM CONGENITAL ATRIOVENTRICULAR BLOCK

Antonio Di Mauro¹, Marco Matteo Ciccone², Federico Schettini¹, Giulia Frasso², Annapaola Zito², Dario Troise³, Paolo Anecchino³, Federica Di Mauro⁴, Pietro Scicchitano², Nicola Laforgia¹.

SUMMARY

Congenital third-degree (complete) atrioventricular block requires pacemaker implantation where prenatal hydrops, low ventricular rate (<45 bpm) non-response to inotropes, and/or left ventricular dysfunction is present. A permanent pacemaker was implanted in a 1200g 9 day old preterm: the smallest newborn successfully subjected to this procedure, according to literature.

Introduction

Congenital complete atrioventricular block (CCAVB) is a congenital arrhythmia characterized by no transmission of any atrial electrical impulses to ventricles, associated with a ventricular back-up system of impulses firing (subsidiary pacemaker) which are generally not compensatory. The overall incidence is about 1/15,000-20,000 per liveborn. In 90% of cases it is caused by the transfer of auto-antibodies (anti-SSA/Ro and anti-SSB/La auto-antibodies) from mothers affected by systemic lupus erythematosus (LES) or Sjogren's syndrome, even during a pre-clinical stage of their autoimmune disease (1-3). These auto-antibodies are responsible for ventricular endocardium damage and subsequent endomyocardial fibroelastosis which can cause intrauterine miscarriage, prolonged QT interval, pre-excitation syndrome and fetal third-degree heart block (2).

The latter is frequently diagnosed at 16-18 weeks of gestation. Timing of delivery, as well as type and time of pacemaker implantation after birth are still controversial issues. Pacemaker implantation is indeed the only treatment for third-degree block and it is immediately required where prenatal hydrops, low ventricular rate (<45 bpm) non-response to inotropes, and/or left ventricular dysfunction are present (3).

In very low birth weight infants (VLBW, i.e. <1500g at birth), a staged pacing strategy has been used, with early temporary epicardial pacing wires then followed by definitive implantation when neonatal body weight reaches 2000g. These steps are undertaken due to the mismatch between generator size and neonatal size. Only a few such cases have been

Address of the authors

¹Section of Neonatology and Neonatal Intensive Care Unit of DIMO, "Aldo Moro" University of Bari, Bari, Italy.

²Section of Cardiovascular Disease of DETO; "Aldo Moro" University of Bari, Bari, Italy.

³Pediatric Heart Surgery, Giovanni XXIII Pediatric Hospital, Bari, Italy.

⁴School of Medicine, "Aldo Moro" University of Bari, Bari, Italy

Send correspondence to: Antonio Di Mauro, dimauroantonio@msn.com

Received: May 16th, 2013 — **Revised:** July 10th, 2013 — **Accepted:** July 24th, 2013

treated with permanent pacemaker implantation (3-5).

We report permanent pacemaker implantation in a 1200g 9 day old preterm, i.e., one of the smallest newborn successfully subjected to this procedure, according to updated literature data.

Case Report

CCAVB (heart rate=56/bpm) was diagnosed in the fetus at 29 weeks of gestation. Mother had no clinical signs of LES, although she resulted positive to both anti-SSA/Ro and anti-SSB/La auto-antibodies. At 31 weeks and 5 days an emergency C-section was performed because of poor fetal movements.

Birth weight was 1619g and Apgar score 5/7. No hydrops was evident. The neonate was immediately intubated because of weak respiratory effort. Electrocardiogram confirmed third-degree heart block with a mean ventricular rate of 50-60/bpm, and no significant heart rate increase after dobutamine (up to 15 μ /kg/min) admini-

stration. T waves were negative in V2-V6 and corrected QT interval duration was 480 msec. Echocardiography showed moderate left ventricular dysfunction. She was extubated on day-of-life (DOL)-3. At DOL-9 (weight=1,200g) exposed to room air, with full enteral feeding, she was evaluated for surgical intervention. Definitive pacemaker implantation was decided upon because of a persistent low ventricular rate (68/bpm). At the Pediatric Cardiology Department of Giovanni XXIII Pediatric Hospital, a 35 cm bipolar steroid-eluting epicardial pacing lead (CapSure Epi 4968; Medtronic) was positioned on the right ventricular free wall through a left antero-lateral thoracotomy at the 5th intercostal space. The pacemaker (MICRONY TM II SR+; St.Jude Medical) was placed in an abdominal pocket, through a left xipho-umbelical paramedian incision, between the rectus muscle sheet and the posterior surface of the abdominal muscle. The exuberant length of the cable was rolled into the left pleural space, tunneled as far as the abdominal pocket and connected to the generator (figure 1).

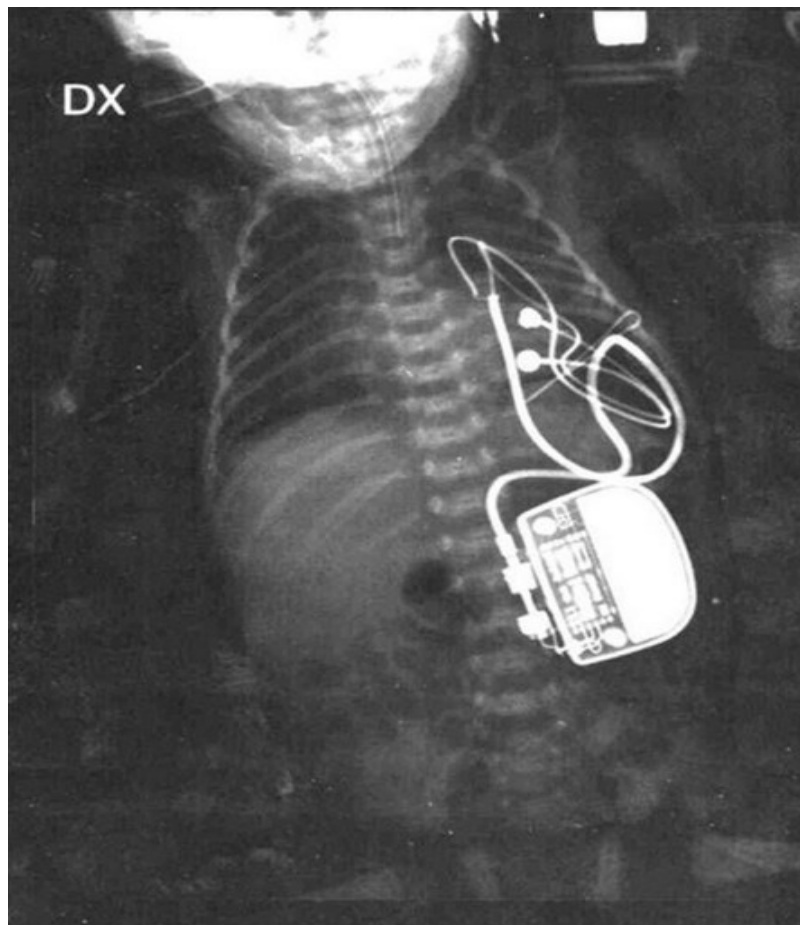


Figure 1: The abdominal positioning of the permanent pacemaker generator implanted.

The pacemaker was programmed with a heart rate of 120 bpm.

After the procedure, the newborn remained intubated and ventilated for 24 hours and was subsequently extubated. Enteral feeding was gradually increased and full enteral feeding was reached 7 days after the procedure. She was discharged at gestational age week 37, weighing 2100g. At ten months of age, growth and psychomotor development were within normal limits and the device was working perfectly and well tolerated.

Discussion

The best treatment for CCAVB, its timing and type of pacing (temporary or permanent), are still debated in very low birth weight infants, when no indications for immediate temporary pacing are present (i.e. prenatal hydrops, low ventricular rate less than 45 bpm and/or ventricular dysfunction) (1-5).

Concerning the timing, it could be harmful to wait for several days without treatment, because of the possibility of sudden death. Therefore, a temporary trans-thoracic pacing is frequently used and then substituted by a permanent pacemaker when the baby's weight exceeds 2000g.

However, temporary pacing has several complications, i.e. electrode ventricular wall perforation, thromboembolism and infections (4).

The intra-diaphragmatic surgical approach with the use of newer bipolar steroid eluting epicardial pacing seems to be effective in VLBW infants (4-5). In our case, because of the absence of response to inotropic drugs, together with a persistent ventricular rate of 68/bpm with signs of left ventricular dysfunction, we decided to implant a permanent pacemaker at DOL9, when the baby's weight was 1200g. The surgical technique avoided the extrapleural approach, because of the risk of respiratory impairment due to restricted lung expansion (4). The intra-abdominal positioning of the pacemaker was well tolerated and the neonate reached full enteral feeding seven days after the procedure. We think that definitive pacemaker implantation could be used in very low birth weight infants because nowadays the very small generators produced help to avoid any of the complications of temporary pacing (4-5). Our case represents, up to

date, the youngest neonate who has undergone this procedure, suggesting that, even in very small neonates with CCAVB, a permanent pacemaker can be safely used.

References

1. Buyon JP, Hiebert R, Copel J, Craft J, Friedman D, Katholi M, et al. Autoimmune-associated congenital heart block: demographics, mortality, morbidity and recurrence rates obtained from a National neonatal lupus registry. *J Am Coll Cardiol* 1998;31:1658-1656.
2. Jaeggi ET, Hamilton RM, Silverman ED, Zamora SA, Hornberger LK. Outcome of children with fetal, neonatal or childhood diagnosis of isolated congenital atrioventricular block. *J Am Coll Cardiol* 2002;39:130-137.
3. Donofrio MT, Gullquist SD, Mehta ID, Moskowitz WB. Congenital Complete Heart Block: Fetal Management Protocol, Review of Literature, and Report of the Smallest Successful Pacemaker Implantation. *J Perinatol* 2004;24:112-117
4. Roubertie F, Le Bret E, Thambo JB, Riques X. Intra-diaphragmatic pacemaker implantation in very low weight premature neonate. *Interact Cardiovascular Thorac Surgery* 2009;9:743-745
5. von Schnakenburg C, Fink C, Peuster M, Wessel A, Vazquez-Jimenez JF. Permanent pacemaker implantation in a 1,445 g pre-term neonate on the first day of life. *Thorac Cardiovasc Surg* 2002;50:363-365.